

INTRAOSSSEOUS ANASTOMOSIS BETWEEN INFRAORBITAL ARTERY AND POSTERO-SUPERIOR ALVEOLAR ARTERY – A SURGICAL GUIDE FOR THE LATERAL WINDOW IN SINUS AUGMENTATION TO AVOID DAMAGING THE ARTERY

Original communication

Eliza Dragan¹, Gabriel Dimofte², Gabriel Melian³, Danisia Haba⁴

“Gr.T. Popa” University of Medicine and Pharmacy, Iași

1. Department of Radiology
PhD student
2. Department of Oncology
3. Department of Maxillofacial Surgery
4. Department of Radiology

INTRAOSSSEOUS ANASTOMOSIS BETWEEN INFRAORBITAL ARTERY AND POSTERO-SUPERIOR ALVEOLAR ARTERY – A SURGICAL GUIDE FOR THE LATERAL WINDOW IN SINUS AUGMENTATION TO AVOID DAMAGING THE ARTERY (Abstract): Objectives: The purpose of this study is to create a 3D printed cutting guide that facilitates precise osteotomy cuts for the lateral window in sinus augmentation, in order to avoid damaging the anastomosis between postero-superior alveolar artery (PSAA) and infraorbital artery (IAO). Material and methods: We examined 3 cadaver heads (6 maxillary sinuses) obtained from the collection of the Department of Anatomy, Université catholique de Louvain, Brussels. CBCT of the skull was performed. Using Planmeca ProModel service, we created the surgical guide for the lateral window. To assess the accuracy of the guide, measurements between reproducible points from the guide and the skull were performed, twice, by 2 independent observers, on planned model and on printed model. Results: The mean value of the differences between the two measurements was 0.69 ± 0.51 mm and ranged from 0.07 to 1.64 mm. Conclusions: The 3D printed surgical guide for the lateral window, in sinus augmentation, reduces intraoperative risks, but does not eliminate the risk of damaging the intraosseous artery. **Key words:** 3D RECONSTRUCTION, ARTERY, SINUS AUGMENTATION, 3D PRINTER

INTRODUCTION

The lateral window approach to sinus augmentation was originally described in 1977 by Tatum (1) and then in 1980 by Boyne and James (2). The goal of this procedure is to increase bone height and volume inferior to the maxillary sinus membrane to enable clinicians to subsequently place dental implants. The lateral approach to sinus augmentation is one of the most predictable regenerative surgical procedures performed in guided bone augmentation surgery, and implant survival is highly successful using a multitude of grafting materials (3, 4, 5).

The goal of this procedure is to supplement bone inferior to the maxillary sinus to enable

clinicians to subsequently place dental implants.

Inaccurate osteotomy cuts to define the lateral window can potentiate bleeding, sinus membrane perforation, septa, alveolar ridge fracture and damage to adjacent teeth. Anatomically, anastomosis between the posterior superior alveolar artery (PSAA) and the infraorbital artery (IAO) is always found at the lateral antral wall. According to the present study, an intraosseous vascular canal at the lateral antral wall has been identified in over 50% of examined CT images the anastomosis formed a concave arch, with the first molar area being the lowest point of the bony canal arch

course. The distance of the canal from the alveolar ridge ranged between 5 and 29 mm (mean 16.9 mm). There is a high probability of transecting the vessel whilst preparing the bony window. It is recommended, therefore, to place the superior border of the osteotomy up to 15 mm from the alveolar crest in classes A, B and C which is sufficient for sinus exposure and placement of long dental implants. In severely atrophic ridges, classes D and E, where the surgeon has a tendency to place the osteotomy of the sinus wall too far cranially, there is a high probability of transecting the vessel (6,7).

Mandelaris, in 2008, introduced a prototype cutting guide that was developed through the use of computerized tomography imaging, computer software and the stereolithographic process to precisely position the lateral wall and facilitate Schneiderian membrane elevation (8).

One of the disadvantages of the stereolithographic guide is the high cost of production.

3D printers can create surgical guides to assist with presurgical planning and provide intraoperative positioning verification. 3D printed surgical guides are fully compatible with conventional CT scanners and new low-radiation, Cone Beam CT (CBCT) scanners. After the scan is taken, the data is converted to .STL format in order to start the planning. The cost of production for this guides is very low.

The purpose of this study is to create a 3D printed cutting guide that facilitates precise osteotomy cuts, in order to avoid damaging the anastomosis between PSAA and IAO.

MATERIAL AND METHODS

We examined 3 cadaver heads (6 maxillary sinuses) obtained from the collection of the Department of Anatomy, Université catholique de Louvain, Brussels.

CBCT of the skull was performed. The protocol for Cone Beam CT (iCAT) was 120 kvp, 18mas, 0.3mm voxel size, 21cm height, 16cm diameter field of view.

Using Planmeca ProModel service and the transparency tool to see the limits of the maxillary sinus, we created the surgical guide for the lateral window (fig. 1).

The surgeon indicated to the Planmeca designer the modality to draw the boundaries of the surgical guide as follows.

The most superior aspect of the lateral access window should be approximately 5 mm below

the superior aspect of the soft tissue reflection. The anterior vertical line is scored just distal to the anterior vertical wall of the antrum. The distal vertical line on the lateral maxilla is approximately 15 mm or more from the anterior. The vertical lines should be at least 8 to 12 mm in height. The inferior line is placed approximately 2 mm above the level of the antral floor. The corners of the access window are usually round (9).

Using the 3D printer Cube X Trio, we created the plastic bone supported cutting guide. The cutting guide defines the precise location of the desired superior cutting path as outlined using the software, as well as the inferior, mesial, and distal boundaries of the previously outlined lateral window using the preoperative plan. In the simultaneous approach, 1 guide can be fabricated to outline the sinus window osteotomy and also guide implant placement, or 2 separate guides can be made.

The borders of the guide define the area in which osteotomy cuts can be made, when creating the lateral window for sinus augmentation, reducing the risk of injuring adjacent teeth, drilling in the alveolar crest or maxillary sinus septa.

Measurements between reproducible points from the guide and the skull were performed, twice, by 2 independent observers, on planned model and on printed model.

- The anterior nasal spine and the most superior, anterior and external point of the guide (M1) ;
- The most inferior and posterior point from the adjacent pterygoid plate and the most superior, posterior and external point from the guide (M2) ;
- The posterior nasal spine and a reproducible point from the inferior point of the guide (M3) ;

RESULTS

The results from the measurements performed on the planned model and on the printed model are showed in Table I.

The mean value of the differences between the two measurements was 0.69 ± 0.51 mm and ranged from 0.07 to 1.64 mm.

DISCUSSIONS

According to Mardinger (10) the bony canal was identified in 55%, with a mean distance of

Intraosseous Anastomosis Between Infraorbital Artery and Postero-Superior Alveolar Artery

TABLE I
Measurements on the planned model and on the printed model

Skull/measurement	Measurements on the planned model			Measurements on the printed model		
	M1	M2	M3	M1	M2	M3
Skull 1	25.52	18.93	41.64	26	19	40
Skull 2	31.61	7.68	33.63	31	7.5	34
Skull 3	19.69	47.64	52.27	21	48.5	53

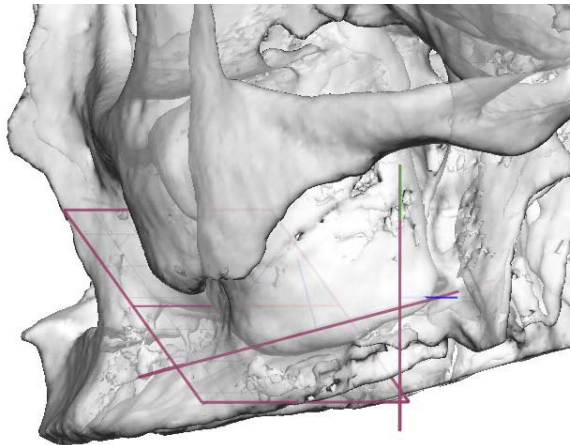


Fig. 1. Using the transparency tool to see the limits of the maxillary sinus, we selected the limits of the guide

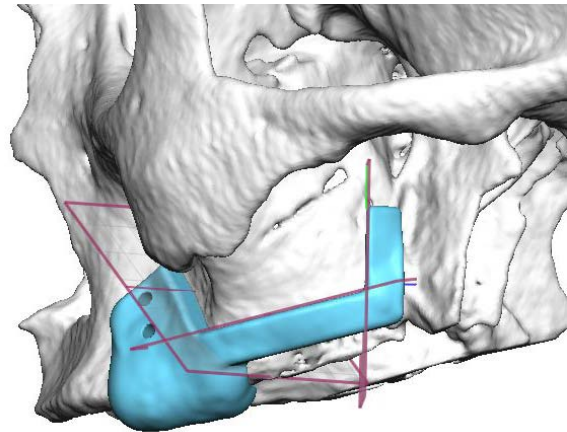


Fig. 2. The surgical guide was created according to the limits established previously

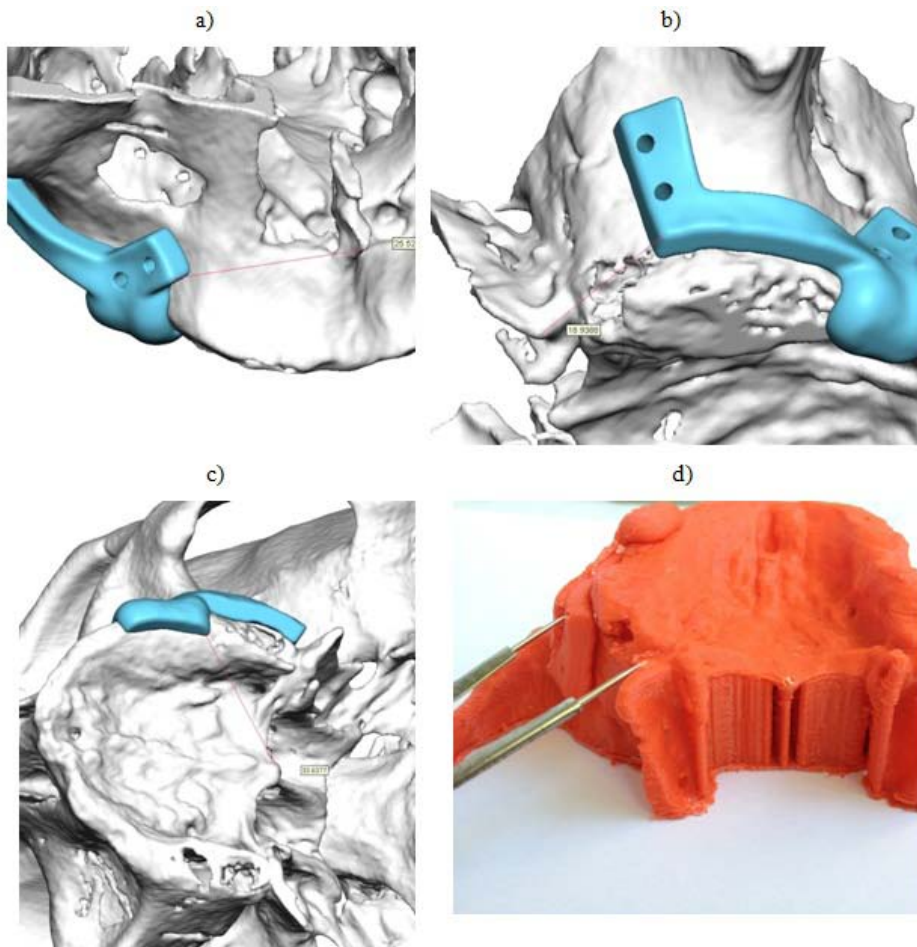


Fig. 3. Measurements on planned model : a) M1, b) M2, c) M3) and on printed model (M2).

16.9 mm from the alveolar ridge. From the examined canals, in 7% the diameter was 2–3 mm wide, in 22% 1–2 mm and in 26% it was less than 1 mm wide. Because only in 50% of cases the vessel was large enough to be detected by a CT scan, it is recommended, to place the superior border of the osteotomy up to 15 mm from the alveolar crest.

According to Rosano (11), an anastomosis between the PSA and the IOA was found by dissection in the context of the sinus anterolateral wall in 100% of cases, while a well-defined bony canal was detected radiographically (CT) in 47% of cases.

The anastomosis displayed three different courses: (1) within the buccal-antral wall cortex; (2) between the Schneiderian membrane and the lateral bony wall of the sinus, in which a small concavity was often visible; and (3) under the periosteum of the sinus lateral wall.

Creating a guide that avoids damaging the intra-osseous artery will reduce the risk of intra-operative bleeding.

Mandelaris created the guide for the lateral window in sinus augmentation, using stereolithography (8). The limitations of the study are: the intra-osseous canal was not taken into consideration, the accuracy of the guide was not evaluated and stereolithography is expensive.

Nowadays, 3D printing improves accuracy of dental implant surgery. It speeds up pre-surgical preparation and eliminates the outsourcing cost of surgical guide production. 3D printed customized surgical guides can be placed onto the patient's teeth before surgery, pinpointing the exact angle and depth needed for the procedure, ensuring correct placement of the implant. The 3D printer allows you to minimize the time needed to create the surgical guides. The 3D guides can be printed within a few hours.

The differences between the 2 measurements performed in our study can be attributed to the following factors: error from the linear measurements, error of positioning of the radio-

opaque markers in comparison to the positioning on the virtual model. The similar results from the measurements are proof for the accuracy of the 3D printed guide.

We applied radio-opaque markers in the established points, on the printed model and guide and we performed the CBCT exam. The software did not allow us to make the measurements neither on 2D sections, nor on the 3D reconstruction. Linear measurements were performed. Also, the course of the intraosseous artery seen on the coronal sections, could not be translated on the 3D reconstruction. The major drawback of this study was the impossibility to translate the 2D markers, on the 3D reconstruction that we used to create the guide.

Another limitation of this surgical guide is that in partially edentulous patients, the positioning of the guide is reproducible, but in totally edentulous patients stabilization pins are recommended.

Due to the fact that the guide is made from plastic, the sterilization process can be performed with Ethylene Oxide.

In future studies we will evaluate the accuracy of the guide on a larger number of skulls.

CONCLUSIONS

The 3D printed surgical guide for the lateral window, in sinus augmentation, reduces intraoperative risks, but does not eliminate the risk of damaging the intraosseous artery.

In comparison to the stereolithographic guides, the 3D printed guides are less expensive, the technological process eliminates the necessity of the radiologic guide and are accurate.

ACKNOWLEDGEMENTS

This work received financial support through the project "Excellence program in multidisciplinary doctoral and postdoctoral research in chronic diseases", contract no. POSDRU/159/1.5/S/133377, beneficiary U.M.F. "Gr.T. Popa" Iasi, financed from the European Social Fund through Sectoral Operational Programme Human Resources Development 2007-2013.

REFERENCES

1. Tatum H: *Lectures presented at the Alabama Implants Study Group*. Birmingham, AL, 1977.
2. Boyne PJ, James RA. Grafting of the maxillary sinus floor with autogenous marrow and bone. *J Oral Surg.* 38(8):613-6, 1980.
3. Froum SJ, Tarnow DP, Wallace SS et al: Sinus floor elevation using anorganic bovine bone matrix (Osteograft/N) with and without autogenous bone: A clinical, histologic, radiographic, and histomor-

Intraosseous Anastomosis Between Infraorbital Artery and Postero-Superior Alveolar Artery

- phometric analysis – Part 2 of an ongoing prospective study. *Int J Periodontics Restorative Dent* ; 18 : 528, 1998.
4. Szabô G, Huys L, Coulthard P et al. A prospective multicenter randomized clinical trial of autogenous bone versus beta tricalcium phosphate graft alone for bilateral sinus elevation : Histologic and histomorphometric evaluation. *Int J Oral Maxillofac Implants* ; 20 : 371, 2005.
 5. Karabuda C, Ozdemir O, Tosun T, et al : Histological and clinical evaluation of 3 different grafting materials for sinus lifting procedure based on 8 cases. *J Periodontol* ; 72 : 1436, 2001.
 6. Elian N, Wallace S, Cho SC et al. Distribution of maxillary artery as it relates to sinus floor augmentation. *J Oral Maxillofac Implants* ; 20 : 784-7, 2005.
 7. Taschieri S. & Rosano G. Management of the alveolar antral artery during sinus floor augmentation procedures. *Int. J. Oral Maxillofac. Surg.* ; 68 : 230, 2010.
 8. Mandelaris G, Rosenfeld AL – Alternative Applications of Guided Surgery : Precise Outlining of the Lateral Window in Antral Sinus Bone Grafting. *J Oral Maxillofac Surg* ; 67 : 23-30, 2009.
 9. Misch CE. Diagnostic evaluation in Misch CE. *Contemporary Implant Dentistry*, 2nd edition, St.Louis : Mosby ; p : 109-118, 1993.
 10. Mardinger O, Abba M, Hirshberg A, Schwartz-Arad D. Prevalence, diameter and course of the maxillary intraosseous vascular canal with relation to sinus augmentation procedure : a radiographic study. *Int. J. Oral Maxillofac. Surg* ; 36 : 735-738, 2007.
 11. Rosano G, Taschieri S, Gaudy JF et al. Maxillary sinus vascular anatomy and its relation to sinus lift surgery. *Clin Oral Implants Res.* ; 22(7) : 711-5, 2011.

Corresponding author

Eliza Dragan
e-mail: elizadrangan@gmail.com