

MAXILLARY SINUS ANATOMIC AND PATHOLOGIC CT FINDINGS IN EDENTULOUS PATIENTS SCHEDULED FOR SINUS AUGMENTATION

Eliza Drăgan¹, Oana (Ladunca) Rusu¹, A. Nemțoi¹, G. Melian¹, C. Mihai¹, Danisia Haba²

University of Medicine and Pharmacy "Grigore T. Popa" - Iasi

Faculty of Dental Medicine

1. Department of Oral and Maxillofacial Surgery

2. Department of General and Oral Radiology

MAXILLARY SINUS ANATOMIC AND PATHOLOGIC CT FINDINGS IN EDENTULOUS PATIENTS SCHEDULED FOR SINUS AUGMENTATION (ABSTRACT) **Objectives:** An aberrant sinus anatomy or pathology can influence the sinus lift technique if it is encountered during surgical exposure. The purpose of the present study was to determine the prevalence of sinus disease and variations of normal anatomy among edentulous patients prior to sinus augmentation. **Material and methods:** 120 patients attending a private surgical practice (53 women and 67 men, with a mean age of 62.02 years, ranging between 34 and 81 years old) for whom treatment was planned for sinus augmentation were evaluated - medical history, radiographic and clinical examinations. Computerized tomograms (CT) and 3D reconstructions from 240 sinuses were analyzed using Dental CT. **Results:** Abnormalities were diagnosed in 74.2% of cases. Mucosal thickening was the most prevalent abnormality (68.3%), followed by retention cysts (15.8%) and opacification (9.2%). The diagnosed conditions included mucosal thickening, chronic sinusitis, sinus cysts and polyps. The prevalence of one or more septa per sinus was found to be 30%. Males present pathology more often than females ($p=0.028$). No statistical correlation could be found between age and pathology ($p>0.05$) No significant differences in age or gender between patients with and without sinus septum were found ($p>0.05$). **Conclusions:** The results reinforce the importance of thorough history taking and clinical and radiographic assessment prior to performing sinus augmentation, to prevent the probability of complications. **Keywords:** SINUS DISEASE, MAXILLARY SINUS SEPTA, SINUS AUGMENTATION, COMPUTER TOMOGRAPHY

The maxilla consists of a variety of anatomic structures, including the maxillary sinus, the lateral nasal wall, the pterygoid plates, associated vasculature structures, and teeth. The maxillary sinus maintains its overall size while the posterior teeth remain in function. It is, however, well known, that the sinus expands with age, and especially when posterior teeth are lost. The average volume of a fully developed

sinus is about 15 ml but may range between 4.5 and 35.2 ml. The sinus cavity expands both inferiorly and laterally, potentially invading the canine region. This phenomenon is the possible result of atrophy caused by reduced strain from occlusal function. One or more septa, termed "Underwood's septa", may divide the maxillary sinus into several recesses. The overall prevalence of one or more sinus septa is between 26.5%

Maxillary sinus anatomic and pathologic CT findings in edentulous patients scheduled for sinus augmentation

and 31% and is most common in the area between the second premolar and first molar. Edentulous segments have a higher prevalence of sinus septa than dentate maxillary segments (1).

The maxillary posterior edentulous region presents more challenging conditions in implant dentistry than any other region of the jaws. However, treatment modalities have developed for this area and allow it to be predictable as any intraoral region. Most noteworthy of these treatments are subantral augmentation to increase available bone height (2).

Diseases associated with the maxillary sinuses include both intrinsic diseases (originating primarily from tissues within the sinus) and those that originate outside the sinus (most commonly diseases arising from odontogenic tissues) that either impinge on or infiltrate the sinus. These types of diseases include inflammatory odontogenic disease (thickened sinus mucosa, polyps, empyema, and retention pseudocysts), odontogenic cysts, benign and malignant odontogenic neoplasms, bone dysplasias, and trauma.

CT has become increasingly important for evaluation of sinus disease and has virtually replaced plane radiography and conventional tomography for investigations of the paranasal sinuses. Because CT provides multiple sections through the sinuses in different planes, they may contribute significantly to delineating the extent of disease and the final diagnosis. High-resolution axial and coronal CT examinations are the most revealing imaging techniques for the paranasal sinuses and the adjacent structures and areas (3).

Previous studies reported the prevalence of incidental abnormalities in CT or CBCT scan in patients' referred to as orthodontic

and maxillofacial purposes, the occurrence of abnormalities is not known in samples of patients who underwent the exam for sinus augmentation procedures (4, 5, 6, 7, 8).

The aim of the study was to determine the prevalence of sinus disease and abnormalities among edentulous patients scheduled for sinus augmentation.

MATERIAL AND METHODS

The study included 120 patients attending a private surgical practice (53 women and 67 men, with a mean age of 62.02 years, ranging between 34 and 81 years) for whom treatment was planned for sinus augmentation. The patients are edentulous in the posterior area of the maxilla. Maxillary computed tomography evaluation is performed for each patient. For statistical analysis, the subjects were divided into the following age groups: 34 – 60 and 61 - 81 years. Computerized tomograms (CT) and 3D reconstructions from 240 sinuses were assessed using Dental CT

CT was performed by using a Tomoscan SR-6000, Philips Medical Systems, Eindhoven, Holland, under the following conditions 1.5 mm slice thickness, 1 mm table feed, 120 kV, $\leq 25-50$ mA/s, 2 s scan time/slice, 512 matrix, native and bone window.

Each observer performed all the measurements separately by using the same computer (17.3-inch diagonal HD+ Bright View LED-backlit Display (1600 x 900), HP Pavilion dv7) and screen resolution (brightness, 300 cd/ m²; resolution, 1,920 × 1,080).

A screening procedure was engaged to identify the presence or absence of sinus abnormalities using the orthogonal views of coronal, axial and sagittal scans.

We considered deviations from normali-

ty partial or complete opacification of the maxillary sinus and increased thickening of the mucosa greater than 1 mm. We considered cases as having a sinus abnormality when both examiners identified at least one type of abnormality and excluded cases in which both examiners diagnosed the absence of an abnormality.

The identification of an abnormality was registered separately for the right and left sinuses of each patient. Selected cases were independently reevaluated by the examiners in order to diagnose and classify the cases into different abnormality sub-

types, such as: mucosal thickening, retention cysts, opacification, sinus polyps, osteoma and odontogenic cysts. The examiners noted the presence of sinus septa.

Assessment of maxillary sinus septum

Every bony prominence more than 4mm wide or 4mm high was considered because a bony prominence is thought to have an impact during elevation of the sinus floor under local anesthesia. The bony septa were transversal, horizontal, sagittal, or atypical, and were complete or incomplete (partial) (3) (fig. 1).

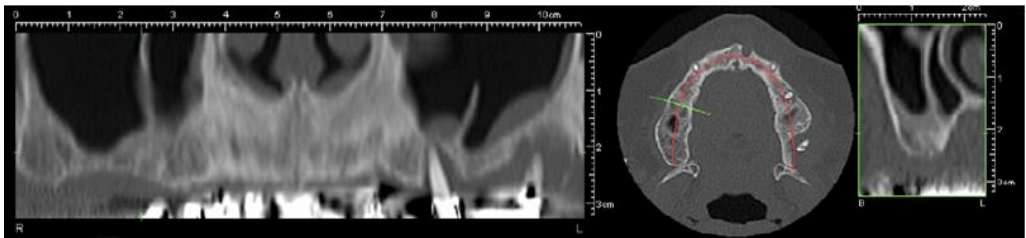


Fig. 1. Bilateral maxillary sinus septum

Assessment of pseudocysts

Whites (3) considers that pseudocysts usually form on the floor of the sinus, although some may form on the lateral walls or the roof. Retention pseudocysts may vary in size from that of a fingertip to completely

filling the sinus and making it radiopaque. Retention pseudocysts usually appear as well-defined, non corticated, smooth, dome-shaped radiopaque masses. Because the lesion originates within the sinus, no osseous border surrounds it (fig. 2).

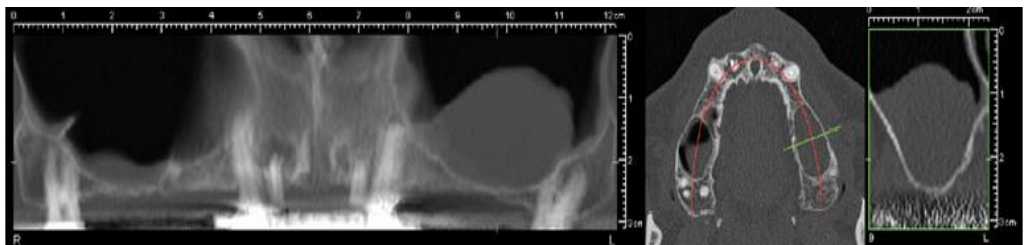


Fig. 2. Left maxillary sinus retention pseudocyst

Assessment of mucosal thickening

The image of thickened mucosa is readily detectable in the radiograph as a non

corticated band noticeably more radiopaque than the air filled sinus, paralleling the bony wall of the sinus. Mucosal thickening was

Maxillary sinus anatomic and pathologic CT findings in edentulous patients scheduled for sinus augmentation

considered present when the thickness of the sinus mucosa was ≥ 1 mm as measured from

the floor of the sinus to the highest border of the mucosa(3) (fig. 3).

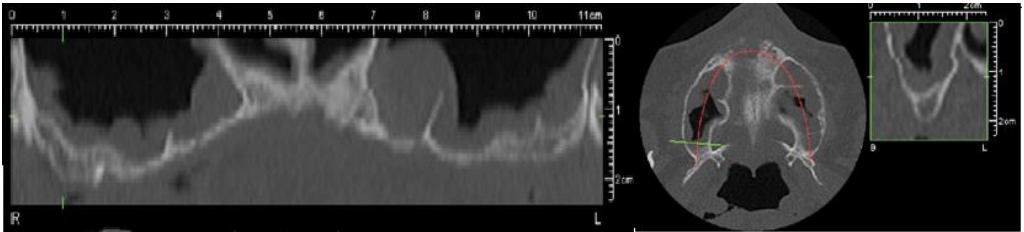


Fig. 3. Bilateral mucosal thickening of the maxillary sinuses

Assessment of sinusitis

Thickening of sinus mucosa and the accumulation of secretions that accompany sinusitis reduce the air content of the sinus and cause it to become increasingly radiopaque. The most common radiopaque pat-

terns that occur are localized mucosal thickening along the sinus floor, generalized thickening of the mucosal lining around the entire wall of the sinus, and near-complete or complete radio opacification of the sinus (3) (fig. 4).

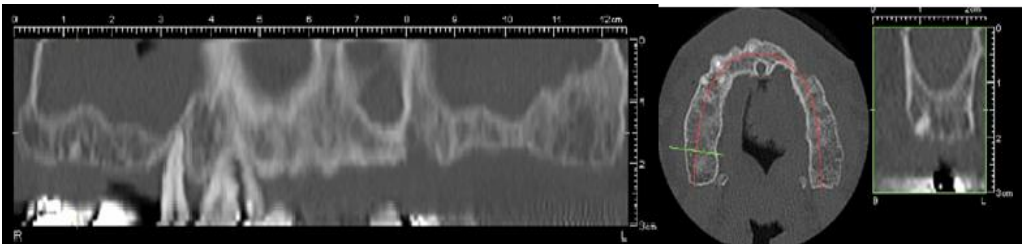


Fig. 4. Bilateral complete opacification of the maxillary sinuses

Assessment of polyps

A polyp may be differentiated from a retention pseudocyst on a radiograph by noting that a polyp usually occurs with a thickened mucous membrane lining be-

cause the polypoid mass is no more than an accentuation of the mucosal thickening. In the case of a retention pseudocyst, however, the adjacent mucous membrane lining is not usually apparent (3) (fig. 5).

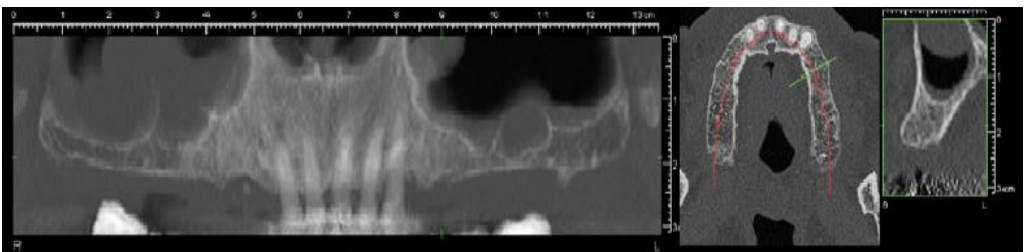


Fig. 5. Polyps in the right maxillary sinus

Assessment of odontogenic cysts

The most common are radicular cysts, followed by dentigerous cysts and odontogenic keratocysts. A thin radiopaque line divides

the contents of the cyst from the sinus cavity. In the case of a radicular cyst, the lamina dura of the involved tooth or teeth is not intact in the apical area (3) (fig. 6).

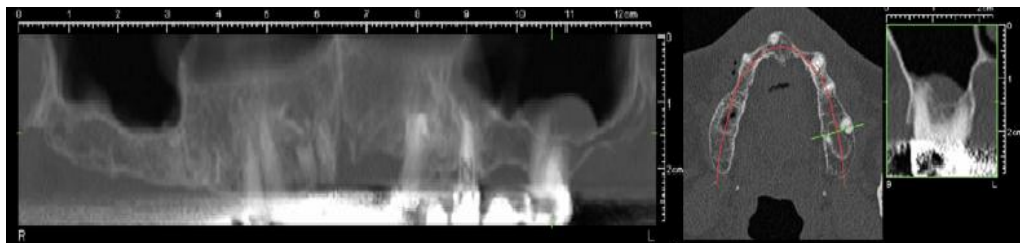


Fig. 6. Odontogenic cyst in relationship with the first left molar

Calibration and reliability

The CT scans were reviewed independently by 2 oral surgeons and 2 maxillofacial surgeons trained by a radiologist with experience of over 1,000 scans at the time of the study. The diagnostic criteria were developed on the basis of the published literature, and in the case of a disagreement, a consensus was reached after a discussion between the observers. Each examiner measured and assessed all the CT images twice.

Statistical analysis

Obtained patient data and scan data were recorded in a SPSS database (IBM). Statistical analysis was performed using SPSS version 20.0 for Windows 7 (IBM). Logistic regression analysis was performed to determine the effects of gender and age on the abnormalities. The level of significance was set at 5%. The chi-square test was used to compare groups. An error probability of <0.05 was accepted as significant.

RESULTS

Mucosal thickening was the most frequently observed abnormality (68.3% of the sinuses). It is generally associated with

some kind of irritation, such as odontogenic pathology or allergic phenomena.

Either one or both sinuses of 9 patients showed total opacification, which would suggest an occurrence of sinusitis. However, sometimes opacification can also be found in abnormalities other than sinusitis, such as mechanical trauma, barotraumas and hemorrhage (9). In addition, a final diagnosis of sinusitis may also be considered when clinical signs and symptoms are present and such factors were not evaluated in this study.

Mucous retention cysts were the second most frequently found inflammatory abnormality (15.8% of the sinuses). This result is similar to other studies (9).

4 of these patients showed polypoidal mucosa.

One patient showed an odontogenic cyst in relationship with the first left molar that evolved towards the maxillary sinus, one patient had a tooth in the sinus and another patient had an osteoma (fig.7). These cases were not considered statistically significant.

In most people the maxillary sinus develops as a single space with various compartments. Usually the septa are incomplete,

Maxillary sinus anatomic and pathologic CT findings in edentulous patients scheduled for sinus augmentation

but in rare cases, complete septa can divide the maxillary cavity. 21.7% of the patients

had unilateral maxillary septum and 8.3% had bilateral maxillary sinus septum.

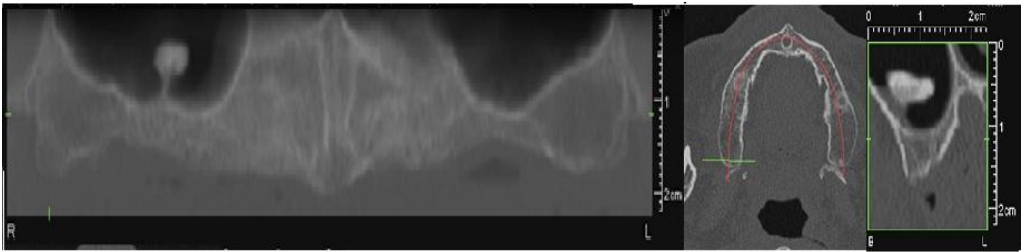


Fig.7. Osteoma in the right maxillary sinus

Pathologic findings in either one or both sinuses were found in 89 patients (74.2%). 49 patients (40.83%) showed pathologic signs in both and 40 patients (59.16%) in either one of their sinus. 31 (25.8%) of the 120 investigated patient scans showed no pathologic signs within either left or right maxillary sinus (tab I).

TABLE I
Findings tabulated for both sinuses, unilateral and bilateral

Findings	Unilateral	Bilateral
Normal	57	31
Mucosal thickening	24	29
Septum	26	10
Pseudocyst	13	3
Complete opacification	7	2
Polyp	2	2
Odontogenic cyst	1	0
Tooth in sinus	1	0
Osteoma	1	0

Out of 67 male patients 44 (65.67%) had at least some pathology in either of the sinuses, whereas only 30 of the 53 investigated scans of female patients (56.6%) showed pathologic signs in either sinus.

Fisher's Exact Test (p=0.029) showed a

statistical correlation between gender and pathology. Males tend to present pathology more often (66.2%) than females (54.7%). The logistic regression results showed an association between gender (p=0.028) and pathology. In terms of odds ratio, the odds of having pathology as a male is higher by 62.4%. There was no correlation between age and pathology (p=0.847)

The logistic regression results showed no association between age (p=0.068) and gender (p=0.773) with the maxillary sinus septa for the study group.

DISCUSSION

Several studies have reported a great variability in the prevalence of incidental findings in the maxillary sinuses of asymptomatic subjects when multiplanar images are used. CT scanning studies found abnormalities in approximately 30% of cases (5, 6) and CBCT studies reported a prevalence ranging from 24.6% to 56.3%. Also, gender and age were significantly associated with pseudocysts (p=0.027) and mucosal thickening (p<0.001, respectively (4, 7, 8). In our study, we detected incidental abnormalities in 74.2 % of the cases and no association between age, gender and sinus conditions. Variations in image interpretation and diagnostic criteria and influence of

the climate among differences geographical areas can influence abnormality rates (4, 5, 6, 10, 11, 12).

Differences in prevalence found in this study compared with the known literature could be explained by several factors. First, different age and patient groups were investigated in the various studies. One study investigated 30 patients with paranasal problems determining a prevalence of up to 63% (13), and another study reported on 202 patients having different indications for CT scanning with a prevalence of 82.2% for mucosal abnormalities (14).

Moreover, the definitions for pathologic changes and the applied classification systems vary among the studies. Another factor could be the visualization quality of the different imaging modalities.

Other studies that evaluated the patients about to undergo sinus augmentation observed that 98% were diagnosed with chronic periodontitis, 51% were smokers, and 27% reported a history of symptoms indicative of sinus disease. Eighteen subjects were diagnosed with sinus disease and/or abnormalities (chronic sinusitis, sinus cysts, nasal septum deviation, and ostium stenosis). No significant differences in age, gender, or smoking status between patients with and without sinus conditions were found (15).

The sinus lift technique may be difficult to perform if an aberrant sinus anatomy is encountered during surgical exposure. Previous studies that evaluated the sinus septa found a prevalence of one or

more septa per sinus to be 26.5%. Another research team from France found that forty-six subjects (61%) had no bony septa or had septa less than 4 mm (16, 17). A study made on edentulous subjects found a prevalence of maxillary sinus septa of 21.58% and no association between age and gender with the maxillary sinus septa (18).

The present study is limited by several factors. The two observers in this study were not trained radiologists but they were clinically experienced oral and maxillofacial surgeons using CT in clinical routine. Blood and pus appear radiological identical and cannot be discriminated.

Inflammation in the paranasal sinus is a frequent disease and can result from a variety of causes such as infection, chemical irritation, allergy, introduction of a foreign body, or facial trauma. Periodontal disease or rarefying or sclerosing osteitis may cause a localized mucositis in the adjacent floor of the maxillary antrum. Malignancies, also, have to be identified. Incidental findings were the main focus of our study and it provides information on the frequency of anatomic and pathologic findings in the maxillary sinus in CT images of edentulous patients.

CONCLUSIONS

The vast majority of the patients had at least one pathological finding. CT is the most appropriate exam to evaluate the maxillary sinus disease and anatomical variations, before sinus floor elevation.

REFERENCES

1. Jan Lindhe, *Clinical Periodontology and Implant Dentistry*, Fifth Edition, Blackwell Publishing Ltd, 2008.
2. Carl E. Misch, *Contemporary Implant Dentistry*, Mosby-Year Book, 1993.
3. Stuart C. White, *Oral Radiology Principles and Interpretation*, Sixth Edition, Elsevier, 2009.

Maxillary sinus anatomic and pathologic CT findings in edentulous patients scheduled for sinus augmentation

4. Jürgen Lutz, MD, Joerg Neugebauer, Martin Scheer, Timo Dreiseidler, Max J. Zinser, Daniel Rothamel, and Robert A. Mischkowski, Prevalence of pathologic findings in the maxillary sinus in cone-beam computerized tomography, - *Oral Surg Oral Med Oral Pathol Oral Radiol Endod* 2011; 111: 634-640.
5. Diamant MJ, Senac MOJR, Gilsanz V, Baker S, Gillespie T, Larsson S: Prevalence of incidental paranasal sinuses opacification in pediatric patients: a CT study. *J Comput Assist Tomogr* 1987; 11: 426-431.
6. Havas TE, Motbey JA, Gullane PJ: Prevalence of incidental abnormalities on computed tomographic scans of the paranasal sinuses. *Arch Otolaryngol Head Neck Surg* 1988; 114: 856-859.
7. Cha J-Y, Mah J, Sinclair P: Incidental findings in the maxillofacial area with 3-dimensional cone-beam imaging. *Am J Orthod Dentofacial Orthop* 2007; 132: 7-14.
8. Pazera P, Bornstein MM, Pazera A, Sendi P, Katsaros C: Incidental maxillary sinus findings in orthodontic patients: a radiographic analysis using cone-beam computed tomography (CBCT). *Orthod Craniofac Res* 2011; 14: 17-24;
9. Inara Carneiro Costa Rege, Thiago Oliveira Sousa, Cláudio Rodrigues Leles and Elismauro Francisco Mendonça, Occurrence of maxillary sinus abnormalities detected by cone beam CT in asymptomatic patients, *BMC Oral Health* 2012.
10. Bolger WE, Butzin CA, Parsons DS: Paranasal sinus bony anatomic variations and mucosal abnormalities: CT analysis for endoscopic sinus surgery. *Laryngoscope* 1991; 101: 56-64.
11. Lim W-K, Ram B, Fasulakis S, Kane KJ: Incidental magnetic resonance image sinus abnormalities in asymptomatic Australian children. *J Laryngol Otol* 2003; 117: 969-972.
12. Rodrigues CD, Freire GF, Silva LB, Fonseca da Silveira MM, Estrela C: Prevalence and risk factors of mucous retention cysts in a Brazilian population. *Dentomaxillofac Radiol* 2009; 38: 480-483.
13. Hahnel S, Ertl-Wagner B, Tasman AJ, Forsting M, Jansen O. Relative value of MR imaging as compared with CT in the diagnosis of inflammatory paranasal sinus disease. *Radiology* 1999; 210: 171-176.
14. Bolger WE, Butzin CA, Parsons DS. Paranasal sinus bony anatomic variations and mucosal abnormalities: CT analysis for endoscopic sinus surgery. *Laryngoscope* 1991; 101: 56-64.
15. Beaumont C, Zafiropoulos GG, Rohmann K, Tatakis DN, Prevalence of maxillary sinus disease and abnormalities in patients scheduled for sinus lift procedures, *J Periodontol.* 2005; 76(3): 461-467.
16. Kim MJ, Jung UW, Kim CS, Kim KD, Choi SH, Kim CK, Cho KS, Maxillary sinus septa: prevalence, height, location, and morphology. A reformatted computed tomography scan analysis, *J Periodontol.* 2006; 77(5): 903-908.
17. Bruno Ella, Reynald Da Costa Noble, Yves Lauerjat, Cyril S'edarat, Narcisse Zwetyenga, Francois Siberchicot, Philippe Caix, Septa within the sinus: effect on elevation of the sinus floor - *British Journal of Oral and Maxillofacial Surgery* 2008; 46: 464-467.
18. Faveri, Marcelo; Ferrari, Daniel S; Melo, Leandro; Garcia, Ricardo Vieira, Prevalence of maxillary sinus septa in 1024 subjects with edentulous upper jaws: a retrospective study, *The Journal of Oral Implantology* 2007; 33(5): 293-296.